

26-26B SURGICAL TREATMENT AND OUTCOMES: POSTEROMEDIAL IMPINGEMENT—DEBRIDEMENT AND ULNAR COLLATERAL LIGAMENT RECONSTRUCTION

JAMES R. ANDREWS, MD, KARIM A. MEIJER, MD, and
JARROD R. SMITH, MD

Introduction

- Elbow arthroscopy and a limited elbow arthrotomy can treat the pathology of posteromedial impingement seen in valgus extension overload.
- The preferred technique is a supine-suspended elbow arthroscopy when treating isolated posteromedial impingement.
- Portal placement is crucial to safe and efficient elbow arthroscopy.
- When performed with a concomitant ulnar collateral ligament (UCL) reconstruction, a vertical arthrotomy is made posterior to the posterior band of the ligament to address posteromedial impingement.
- Both arthroscopic and open decompression of posteromedial impingement have reported favorable results in the literature.
- UCL reconstruction is a successful procedure to return overhead athletes to play.
- The preferred technique is a modified Jobe technique.

- The preferred graft is a palmaris longus autograft.
- Transposition of the ulnar nerve is a crucial portion of the procedure.

Posteromedial Impingement Surgical Technique

Both elbow arthroscopy and a limited elbow arthrotomy can treat the pathology of posteromedial impingement seen in valgus extension overload. The preferred technique of the senior author depends on whether a concomitant UCL reconstruction is being performed. When in isolation, the preferred technique is a supine-suspended elbow arthroscopy. However, with a UCL reconstruction and when the ulnar nerve is transferred, an open decompression is performed through a limited posteromedial capsular arthrotomy.

ELBOW ARTHROSCOPY

The patient is placed supine on the operating room table. After induction of general anesthesia, the table is turned 90 degrees to create sufficient operative space. The operative limb is placed in traction with a balanced suspension of 5 to 8 lb of weight. The arm should be suspended at rest at approximately 90 degrees of flexion at the elbow (Fig. 26B.1). The arm is prepped and draped in standard fashion based on the surgeon's preference with a tourniquet. Video monitors are positioned over the contralateral shoulder of the patient and torso of the patient. Two video monitors are used to switch between a 4.0-mm, 30-degree arthroscope and a 2.7-mm, 30-degree arthroscope depending on which compartment within the elbow is being visualized. A pump is optional and when used is set to 35 mm Hg to maintain joint distention. Nonvented cannulas are used to minimize fluid extravasation. The 4.0-mm, 30-degree arthroscope is used in the anterior and posterior compartment, and the 2.7-mm, 30-degree arthroscope is used in the lateral compartment through the direct lateral or "soft spot" portal. Important landmarks such as the lateral epicondyle, medial epicondyle, radial head, olecranon, and ulnar nerve are palpated and marked with a surgical pen.

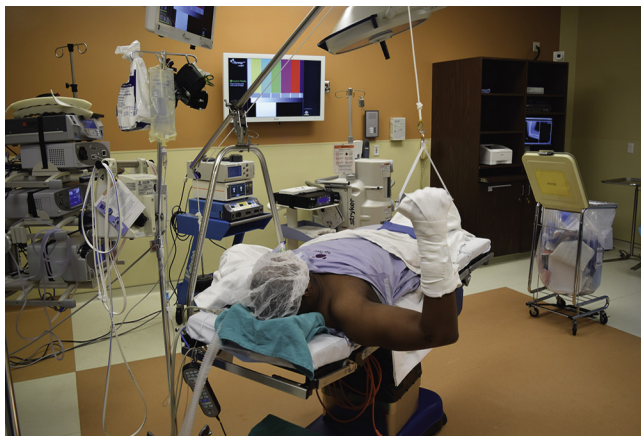

Fig. 26B.1 Operating room setup.

Portal placement is crucial to safe and efficient elbow arthroscopy. Before starting, 30 to 40 mL of normal saline is used to distend the joint through the "soft spot" portal via an 18-gauge spinal needle. This "soft spot" portal lies in the triangle formed by the radial head, lateral epicondyle, and olecranon. A second spinal needle is placed in the antero-lateral portal, which is located approximately 1 cm anterior to the lateral epicondyle. Back flow of fluid confirms intraarticular placement of the spinal needle. A #11 blade is used to make a small skin incision in line with the spinal needle. Blunt hemostats are used to dilate the incision while a blunt trocar is used to penetrate into the anterior compartment of the elbow. The 4.0-mm, 30-degree arthroscope is used to view the anterior compartment. The coronoid and trochlea are visualized within the anterior compartment. Furthermore, flexion and a valgus load can be applied with the help of an assistant to view the UCL and assess for stability. This is typically done in approximately 70 degrees of flexion. It has been reported that an opening of 1 to 2 mm between the medial trochlea and coronoid is indicative of injury to the anterior bundle of the UCL (Field & Altchek, 1996). If needed, an anteromedial portal may be established through direct visualization. An 18-gauge spinal needle is introduced approximately 1 cm distal and 2 cm anterior to the medial epicondyle. It is important to always palpate the medial intermuscular septum and to remain anterior to this landmark. We do not routinely use this portal when addressing posteromedial impingement; however, it can be useful for inspection of the anterolateral compartment of the elbow including the radiocapitellar joint.

Next, the "soft spot" portal is created with a #11 blade in the same trajectory previously used to distend the joint before beginning the arthroscopy. A 2.7-mm, 30-degree arthroscope is used to visualize the lateral compartment of the elbow. Through this portal, the posterior aspect of the radial head, proximal radioulnar joint, capitellum, and olecranon can be visualized. The 4.0-mm, 30-degree arthroscope remains in the anterior compartment to provide fluid to the joint. It is important to maintain the arthroscope within the anterior compartment to prevent any extraarticular fluid extravasation. The use of the "soft spot" portal provides a means to create a posterolateral portal under direct visualization. The posterolateral portal is 3 cm proximal to the tip of the olecranon and just lateral to the edge of the triceps tendon along the lateral epicondylar ridge. A spinal needle is used to confirm the intraarticular placement of the portal under direct visualization. The joint capsule is robust in this area, and blunt penetration with a trocar can be difficult. Therefore a #11 blade is used under direct visualization to make the portal. After the trocar is positioned, the 4.0-mm, 30-degree arthroscope is moved to the posterior compartment. At this point, the assistant extends the elbow to about 30 degrees of flexion to create the posteromedial portal. This portal is placed approximately 1 to 2 cm proximal to the tip of the olecranon and just off the medial edge of the triceps (Fig. 26B.2). Sometimes this portal is placed transtendinous through the triceps. However, we try to avoid a transtendinous placement in overhead throwing athletes to reduce any possible source of pain as the elbow is fully extended during the throwing motion. The key is to make sure this portal provides approximately a 90-degree angle in terms of the instrumentation with the posterolateral portal.

The posterolateral portal is used as the “viewing portal,” and the posteromedial portal becomes the “working portal” when addressing the pathology associated with posteromedial impingement. The soft tissue is cleared with a 4.5-mm arthroscopic shaver and decompression of the osteophytes is done with a hooded 5.5-mm arthroscopic bur (Fig. 26B.3). The elbow is placed in near full extension to assist in debridement of the osteophyte while flexing of the elbow allows for evaluation of the humeral articular cartilage. Often, a “kissing lesion” on the trochlea can be seen and may need to be debrided. Radiographs or computed tomography (CT) scans (or both) are used preoperatively to evaluate the posteromedial osteophytes and should be present and viewed in the operating room before and during the operation. Overzealous resection of the osteophytes can preload the UCL. Care should be taken to resect only pathologic bone while leaving normal bone. Often, a fibrous union can be seen on radiographs or CT. A banana blade can be used to enter the fibrous union and dislodge the pathological osteophyte. Furthermore, axial traction with the elbow at 90 degrees of flexion can be used to assist in resection of the osteophyte. This technique creates a few millimeters of space between the olecranon and humerus, which helps define the underlying articular cartilage of the trochlea. After completion of the decompression, the arthroscope is placed in the posteromedial portal and the posterior compartment is evaluated for any loose bodies and any bony pieces that came loose from the decompression.

The skin portals are closed with #3-0 Ethilon (Ethicon, Somerville, NJ) suture, and a full-length compressive, sterile

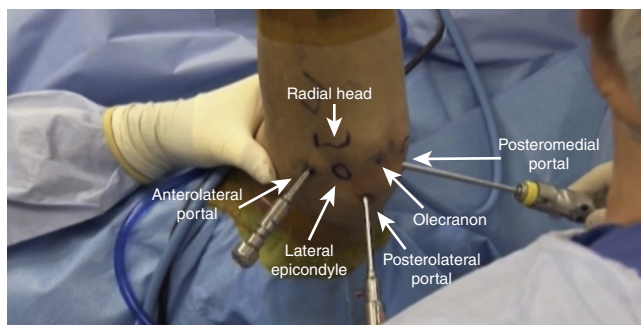


Fig. 26B.2 Portal placement.

dressings is applied. The patient is placed in a simple sling and educated on range of motion (ROM) exercises of the shoulder, wrist, and hand. Often, a medium Hemovac drain is placed through the anterolateral portal for the first 24 hours. Gentle active and active-assisted exercises are begun immediately with passive ROM started on postoperative day 5. Aggressive early ROM exercises can cause drainage through the posterior portals and a sinus can potentially develop or even a postoperative wound infection. Motion exercises are progressed through week 3 until further strengthening and eccentric exercises are started. At 6 weeks, an interval-throwing program is started with return to full time activities by 12 to 16 weeks.

OPEN DECOMPRESSION

The standard operative setup and approach to the elbow used for a UCL reconstruction as previously described is used for an open decompression and excision of posteromedial osteophytes. Before drilling the ulnar and humeral tunnels and after the ulnar nerve has been completely mobilized, a 1- to 2-cm vertical arthrotomy is made posterior to the posterior band of the UCL from the medial epicondyle to the tip of the olecranon. This allows for retraction and complete visualization of the posteromedial olecranon osteophytes from the medial side. A one-quarter inch osteotome is used to excise the osteophytes in addition to a 4.0-mm round bur (Stryker) for fine-tuning the posteromedial olecranon. The ulnar nerve is protected with army-navy retractors, and the elbow is placed in approximately 30 degrees of flexion with a valgus stress. Copious bulb irrigation is used to clear the joint of bone debris and improve visualization. The elbow is brought through an ROM to ensure adequate motion and elimination of bony impingement. The arthrotomy is closed with #1 absorbable braided suture before continuing with UCL reconstruction. The postoperative course is dictated by the UCL reconstruction protocol.

Posteromedial Impingement Outcomes

Both arthroscopic and open decompression of posteromedial impingement have reported favorable results in the literature (Andrews & Carson, 1985, 1995; Cain, 2010;

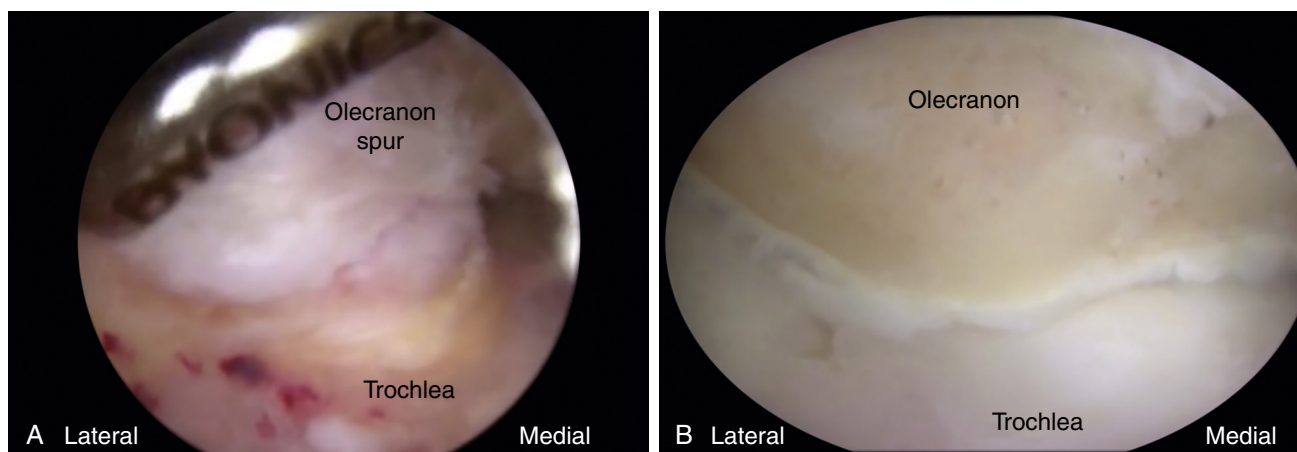


Fig. 26B.3 Before (A) and after (B) pictures of an arthroscopic decompression of a posteromedial osteophyte.

Cohen et al, 2011; Rahusen et al, 2009; Reddy et al, 2000; Wilson et al, 1983). The first reported description of posteromedial impingement was reported by Wilson et al (1983) on five pitchers who underwent an open decompression. All five were able to return to pitching for a minimum of one full season at maximum effectiveness with an average time to return of 11 weeks (Wilson et al, 1983). One of the five patients required a second operation for recurrent symptoms. Open management of posteromedial impingement still remains the senior author's preference when performed in conjunction with a UCL reconstruction or ulnar nerve transposition. Cain et al (2010) reported no difference in return-to-play outcomes for players who had a concomitant open posteromedial olecranon excision during the index UCL reconstruction (86%) versus those without excision (82%) ($P = 0.21$).

As arthroscopic techniques have continued to advance, the management of posteromedial impingement is more commonly treated arthroscopically (Andrews & Timmerman, 1995; Cain et al, 2010; O'Holleran & Altchek, 2006; Rahusen et al, 2009; Reddy et al, 2000). In a large series Reddy et al (2000) reported that 47 of 55 (85%) professional athletes returned to previous level of play after arthroscopic treatment of posteromedial impingement and 87% reported "good" to "excellent" results (Reddy et al, 2000). Furthermore, Rahusen et al (2009) reported on 16 patients treated for posterior impingement of the elbow with an increase in Modified Andrews' Elbow Scoring System (MAESS) scores from 69 (average score) preoperatively to 93 (excellent score) postoperatively. Cohen et al (2011) reported on a series of 9 pitchers (5 professional and 4 recreational) with posteromedial elbow impingement treated arthroscopically. On the basis of Andrews-Carson scale, the subjective and objective outcomes were considered excellent in 7 patients and good in 2. Last, Hepler et al (1998) found a postoperative satisfaction rate of 91% in patients treated arthroscopically for posteromedial impingement.

Although arthroscopic techniques have demonstrated good to excellent results, the reoperation rate after an isolated arthroscopic debridement of posteromedial osteophytes has been reported to be as high as 41% (Andrews & Timmerman, 1995). Furthermore, Cain et al (2010) reported 10 of 53 (19%) patients who underwent posteromedial decompression returned for a secondary procedure on average at 25.4 months (range, 4.5–72.4) from the index procedure. Return-to-play for this cohort was 71% (38 of 53). In addition, Andrews and Timmerman (1995) reported that after removal of a posteromedial osteophyte, 25% of patients eventually required an UCL reconstruction. The authors suspected the reason for this was either loss of the posteromedial buttress or failure to initially appreciate the severity of the underlying associated UCL injury.

Ulnar Collateral Ligament Reconstruction Surgical Technique

The senior author's preferred graft choice for UCL reconstruction is the ipsilateral palmaris tendon. If the tendon

is absent or insufficient, the contralateral gracilis tendon is used. The senior author prefers to harvest the gracilis tendon using a minimally invasive popliteal incision. The following surgical technique describes UCL reconstruction with ipsilateral palmaris autograft using the modified Jobe technique.

GRAFT HARVEST AND PREPARATION

The patient is placed in the supine position on the operating room table, and the operative extremity is placed on a hand table. A nonsterile tourniquet is placed on the extremity, and it is prepped and draped in standard fashion. Coban (3M, Maplewood, MN) is wrapped around the hand, being sure not to cover the incision sites for palmaris harvest. An Ioban (3M) drape is placed on the remaining exposed skin of the operative extremity. The extremity is exsanguinated, and the tourniquet is inflated to 250 mm Hg.

Two 1-cm incisions are then made over the palmaris tendon on the volar aspect of the forearm. The distal incision should be made over a wrist crease to improve cosmesis. The proximal incision should be created 2 to 3 cm proximal to the first incision. Blunt dissection is used to expose the palmaris tendon through both incisions. Care must be taken to coagulate bleeding vessels within these incisions because a hematoma can form in this area and compress the median nerve. The palmaris tendon is isolated by placing a curved hemostat beneath the tendon through each incision (Fig. 26B.4). The median nerve must be protected during retrieval of the palmaris tendon as it lies just deep to the palmaris tendon. The wrist is then flexed, and the tendon is transected using a scalpel through the distal incision. The tendon should be transected as distally as possible to ensure adequate graft length. The tendon is retrieved through proximal incision, and a 0 Ti-Cron (Covidien, New Haven, CT) suture is used to place a locking stitch that will be used for graft passage (Fig. 26B.5).

Tension is pulled on the transected tendon so that it is easier to palpate in the proximal forearm. A third transverse incision is made over the musculotendinous junction of the palmaris, approximately 15 cm proximal to

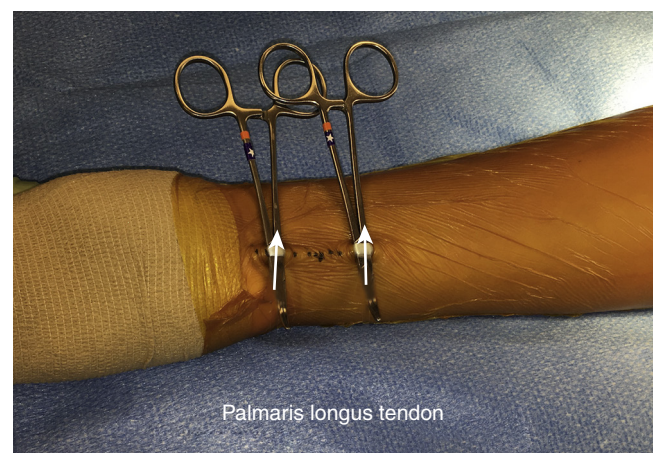


Fig. 26B.4 Palmaris longus tendon isolated in both distal wrist incisions.

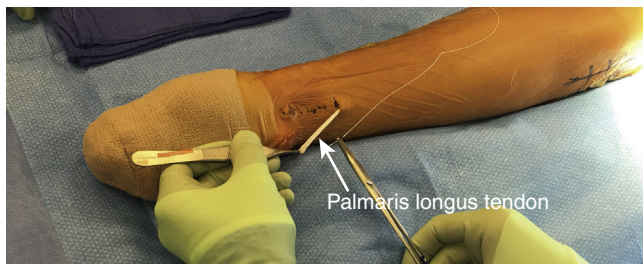


Fig. 26B.5 Transected palmaris longus tendon retrieved through the proximal wrist incision.

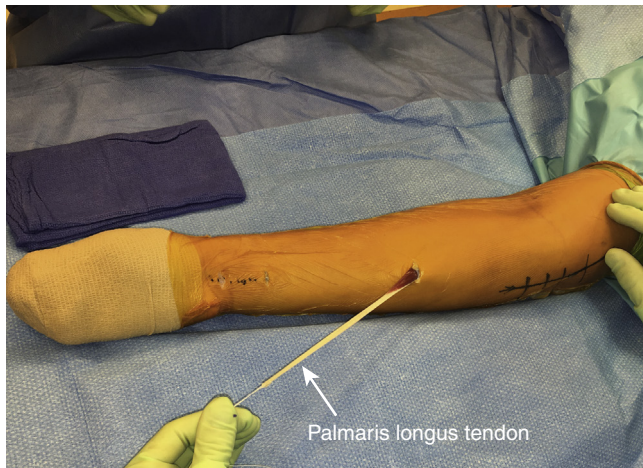

Fig. 26B.6 Palmaris longus tendon retrieved through the volar forearm incision.

the proximal wrist incision. Blunt dissection is performed down to the forearm fascia, and any bleeding vessels are coagulated. The forearm fascia is split longitudinally, and a curved hemostat is placed beneath the palmaris musculotendinous junction. The palmaris tendon is retrieved through the third incision using the curved hemostat. Tension is pulled on the tendon to increase graft length (Fig. 26B.6). Muscle fibers are removed from the proximal portion of the palmaris tendon. The tendon is transected, and a 0 Ti-Cron (Covidien) suture is used to place a locking passing stitch in this end of the tendon. The minimum graft length is 13 cm, but it should be made as long as possible. When the graft harvest is completed, the small longitudinal fascial split in the third incision is closed with 2.0 Vicryl (Ethicon). If this fascial split is not closed, a muscular herniation can occur. Skin incisions are closed with simple, interrupted 3.0 Prolene (Ethicon). The graft is then taken to the back table and placed in a basin.

ULNAR COLLATERAL LIGAMENT RECONSTRUCTION

An incision is made, centered over the medial epicondyle. The incision forms a 160-degree angle, with the proximal limb extending 3 cm from the central aspect of the medial epicondyle and the distal limb extending 6 cm distally (Fig. 26B.7). Blunt dissection is carried out down to the forearm fascia. The

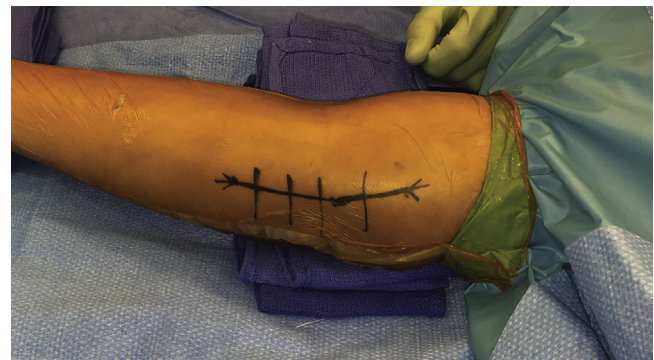

Fig. 26B.7 Incision for ulnar collateral ligament reconstruction.

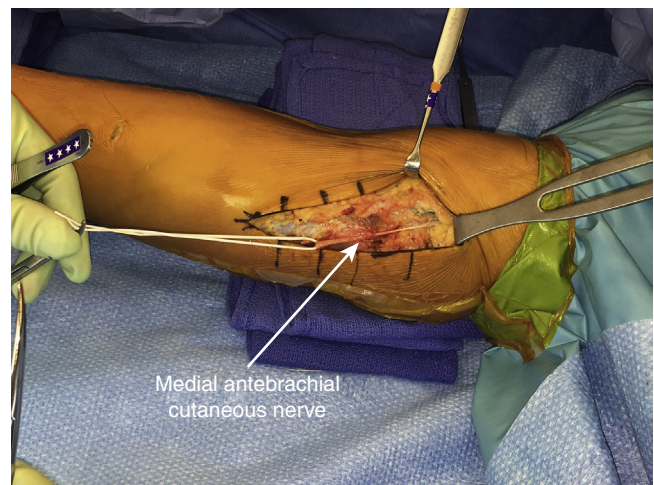


Fig. 26B.8 Medial antebrachial cutaneous nerve placed within a vessel loop.

medial antebrachial cutaneous nerve is identified, and a vessel loop is placed around it (Fig. 26B.8). The nerve typically crosses the field in the distal one third of the incision, but its course can be quite variable. Care must be taken to free the nerve proximally and distally to ensure that it can be retracted either anteriorly or posteriorly during ulnar nerve exposure and tunnel drilling.

The ulnar nerve is identified within the wound proximally, beneath the fascia of the medial head of the triceps. It lies just posterior to the medial intermuscular septum, deep to the fascia. The skin and subcutaneous tissue are retracted, and the ulnar nerve is circumferentially freed proximally from Osborne's ligament through the arcade of Struthers. A vessel loop is then placed around the ulnar nerve. Osborne's ligament is divided, revealing the ulnar nerve in the cubital tunnel. The UCL lies deep to the ulnar nerve here. Distal to Osborne's ligament, the fascia overlying the flexor carpi ulnaris (FCU) is divided to the distal extent of the incision. A periosteal elevator is used to bluntly divide the two heads of the FCU, revealing the ulnar nerve in the proximal aspect of the forearm. The ulnar nerve is then circumferentially freed throughout its course within the incision (Fig. 26B.9). Moving distally from Osborne's ligament, the first and second motor branches to the FCU should be identified and protected.

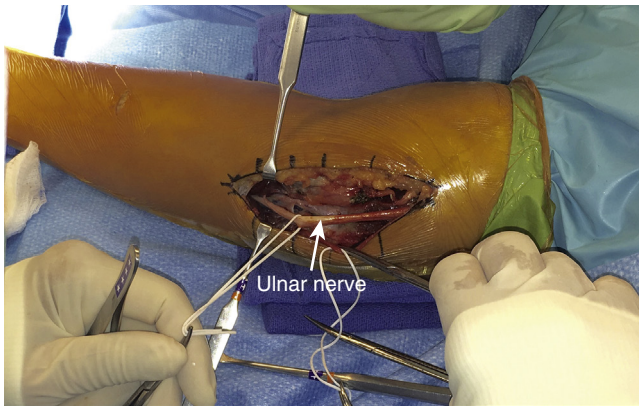


Fig. 26B.9 Ulnar nerve circumferentially freed and placed within a vessel loop.

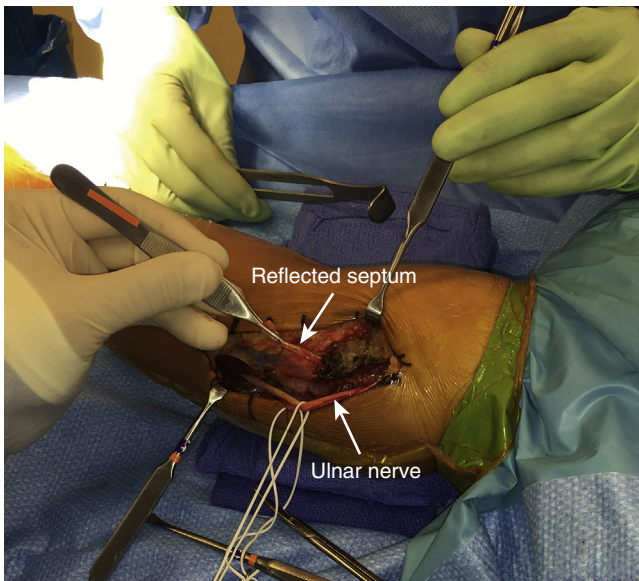


Fig. 26B.10 Medial intermuscular septum reflected for later use as a sling.

The medial antebrachial cutaneous and ulnar nerves are retracted posteriorly, and the medial intermuscular septum is transected 4 cm from the medial epicondyle. The transected portion of the septum is reflected distally for later use as a sling during ulnar nerve transposition (Fig. 26B.10). It should be noted that the distal portion of the medial intermuscular septum should be left attached to the medial epicondyle. Vessels in this area must be coagulated to prevent hematoma formation.

With the medial antebrachial cutaneous and ulnar nerves still retracted posteriorly, the UCL is identified. The origin of the flexor digitorum sublimis (FDS) is reflected off the sublime tubercle of the ulna, exposing the entire UCL. The dissection of the FDS away from the underlying ulna and UCL should proceed in a distal to proximal direction, being careful not to detach the flexor-pronator mass from the medial epicondyle. A small Hohmann retractor is placed on the radial side of the ulna to retract the fibers of the FDS away from the UCL. The anterior band of the UCL is split in

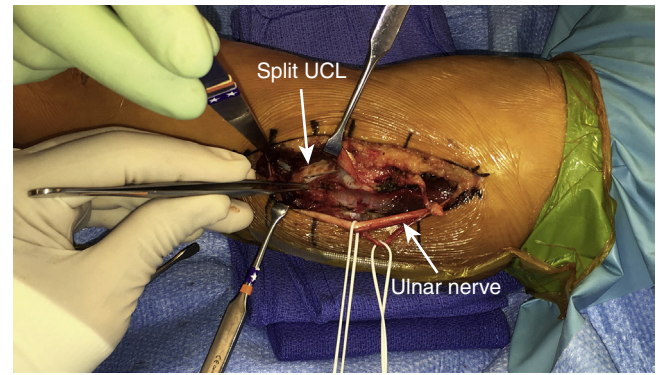


Fig. 26B.11 Longitudinal split in the ulnar collateral ligament. UCL, Ulnar collateral ligament.

line with its fibers, and the ligament is inspected for injury (Fig. 26B.11). The split in the ligament also allows for visualization of the joint line, which is crucial for drilling of the ulnar tunnel. If intraligamentous calcifications are present, they are removed at this point. Furthermore, if an open posteromedial decompression is planned, it is also performed at this point, as described earlier.

The ulnar tunnel is then created by drilling two converging 3.5-mm tunnels at the sublime tubercle, approximately 5 to 7 mm distal to the joint line. The first tunnel is placed posteriorly, while the second tunnel is placed anteriorly. Care should be taken not to violate the joint surface when drilling this tunnel. The tunnel is completed using #1 and #2 curved curettes. A Hewson suture passer (Smith & Nephew, London, UK) is used to pass the graft through the ulnar tunnel.

The humeral tunnel is a Y-shaped tunnel. It is created by first drilling a 3.5-mm tunnel beginning at the humeral origin of the UCL. Two more converging tunnels are placed on the posterior aspect of the medial epicondyle, so that they both connect with the first tunnel. All three tunnels in the humerus are connected using a combination of straight and curved curettes.

The graft is passed through the humeral tunnel in a figure-of-eight fashion. The elbow is flexed to 30 degrees, and tension is pulled on both limbs of the graft. Full elbow ROM is ensured before the graft is secured to the medial epicondyle. The graft is secured into place posterior to the medial epicondyle by placing five simple stitches using 0 Ti-Cron (Covidien). Each of these sutures should secure both limbs of the graft to the humeral periosteum. After the graft is secured posteriorly, the arm is placed into full extension. Additional graft tension is created by incorporating both limbs of the graft into the repair of the split that was previously created in the UCL (Fig. 26B.12). This is also accomplished by using 0 Ti-Cron. Excess graft is sharply removed.

After the graft is sutured into place, the ulnar nerve is transposed anteriorly. The nerve is placed anterior to the medial epicondyle, and the reflected portion of the medial intermuscular septum is used to create a loose sling (Fig. 26B.13). The sling is secured to the forearm fascia using 4.0 Ti-Cron (Covidien). Care must be taken not to strangulate the ulnar nerve beneath the sling. Osborne's ligament is repaired

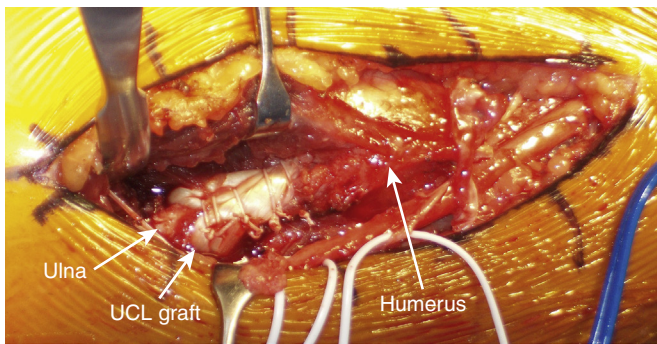


Fig. 26B.12 Ulnar collateral ligament (UCL) graft sutured to the native UCL.

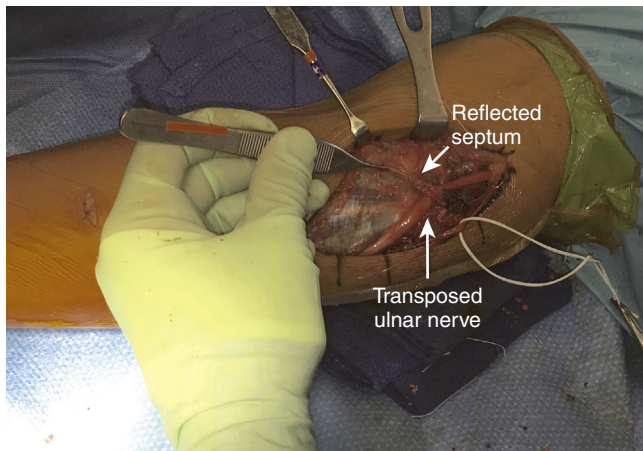


Fig. 26B.13 Transposed ulnar nerve beneath the septum formed by the portion of the intermuscular septum that was previously reflected.

with 0 Ti-Cron (Covidien) to prevent the ulnar nerve from subluxating posteriorly into the cubital tunnel.

The FCU fascia is closed with 0 Ti-Cron (Covidien). Care must also be taken while closing the FCU fascia, so as not to strangulate the ulnar nerve. A 2-cm opening between the two heads of the FCU should be left for passage of the ulnar nerve back into its muscular bed in the forearm. Another 0 Ti-Cron (Covidien) is used to sew a small portion of the medial portion of the triceps over the graft on the posterior aspect of the humerus. This minimizes bleeding and prevents anterior subluxation of the medial head of the triceps. A Hemovac drain is placed, and the tourniquet is deflated. When meticulous hemostasis is obtained, the skin is closed with 2.0 Vicryl followed by 3.0 running Prolene. Sterile dressing is applied, and a posterior splint is placed with the arm in 90 degrees of flexion. The splint will remain on for 5 days. After the splint is removed, the extremity is placed in a hinged elbow brace, which is removed during physical therapy sessions to perform aggressive ROM exercises.

Ulnar Collateral Ligament Reconstruction Outcomes

Overall, UCL reconstruction has been successful in allowing patients to return to play. [Cain et al \(2010\)](#) reported results on 743 patients undergoing UCL reconstruction with at least 2-year follow-up. Eighty-three percent of patients returned to the same level of play or higher. When considering Major League Baseball players, 75.5% returned to the same level of play. Minor league baseball players demonstrated a 73% return to the same level of play or higher. Eighty-seven percent of collegiate baseball players returned to play either collegiate or professional baseball after UCL reconstruction. Eighty-three percent of high school athletes returned to previous level of competition. Additionally, there was a 20% overall complication rate in the study. Sixteen percent of all patients undergoing UCL reconstruction experienced transient ulnar nerve neuropraxia, with the vast majority resolving by 6 weeks.

[Osbaahr et al \(2014\)](#) reported 10-year results on the same cohort of patients. Ninety percent of pitchers were able to return to the same level of play or higher. Overall, baseball players who returned to play were able to continue their careers for an average of 3.6 years. Ninety-three percent of patients were satisfied with their results after their playing careers were finished. Only 3% experienced persistent elbow pain.

References

- Andrews JR, Carson WG. Arthroscopy of the elbow. *Arthroscopy*. 1985;1(2):97–107.
- Andrews JR, Timmerman LA. Outcome of elbow surgery in professional baseball players. *Am J Sports Med*. 1995;23(4):407–413.
- Cain EL Jr, Andrews JR, Dugas JR, et al. Outcome of ulnar collateral ligament reconstruction of the elbow in 1281 athletes: results in 743 athletes with minimum 2-year follow-up. *Am J Sports Med*. 2010;38(12):2426–2434.
- Cohen SB, Valko C, Zoga A, Dodson CC, Ciccotti MG. Posteromedial elbow impingement: magnetic resonance imaging findings in overhead throwing athletes and results of arthroscopic treatment. *Arthroscopy*. 2011;27(10):1364–1370.
- Field LD, Altchek DW. Evaluation of the arthroscopic valgus instability test of the elbow. *Am J Sports Med*. 1996;24(2):177–181.
- Hepler M, Steinman S, Rosenwasser M. Elbow arthroscopy in the treatment of posterior olecranon impingement. *Arthroscopy*. 1998;14:430.
- O'Holleran JD, Altchek DW. The thrower's elbow: arthroscopic treatment of valgus extension overload syndrome. *HSS Journal*. 2006;2(1):83–93.
- Osbaahr DC, Cain EL, Raines BT, Fortenbaugh D, Dugas JR, Andrews JR. Long-term outcomes after ulnar collateral ligament reconstruction in competitive baseball players: minimum 10-year follow-up. *Am J Sports Med*. 2014;42(6):1333–1342.
- Rahusen FTG, Brinkman J, Eygendaal D. Arthroscopic treatment of posterior impingement of the elbow in athletes: a medium-term follow-up in sixteen cases. *J Shoulder Elbow Surg*. 2009;18(2):279–282.
- Reddy AS, Kvitne RS, Yocum LA, ElAttrache NS, Glousman RE, Jobe FW. Arthroscopy of the elbow: a long-term clinical review. *Arthroscopy*. 2000;16(6):588–594.
- Wilson FD, Andrews JR, Blackburn TA, McCluskey G. Valgus extension overload in the pitching elbow. *Am J Sports Med*. 1983;11(2):83–88.